

Non-surgical but efficacious technique for diabetic foot treatment

✉ Reinaldo Martínez¹, Eduardo Montano², Dachel Pérez³, Omaidá Torres¹, Juan F Tejera¹, Lorenzo González¹

¹Hospital Julio Trigo López

Calzada de Bejucal Km 7½, La Esperanza, Arroyo Naranjo, La Habana, Cuba

²Hospital Psiquiátrico Isidro de Armas

10 de Octubre, La Habana, Cuba

³Servicio de Angiología. Hospital Julio Trigo López

Arroyo Naranjo. La Habana, Cuba

E-mail: reimartinez@infomed.sld.cu

ABSTRACT

An increasing portion of diabetic foot ulcer (DFU) patients does not positively responds to common treatments, resulting in partial or complete amputation of the affected limb. DFUs become a health problem, involving several medical specialties, especially Angiology and Endocrinology. There are no products available in the market to treat Wagner grade 3 and 4 ulcers, neither extensive, nor ischemic ulcers. For this purpose, an observational, descriptive, longitudinal and prospective study was carried out to evaluate the therapeutic response of DFU patients who were admitted at the angiology service of the General Teaching Hospital Julio Trigo, from January to June 2010. This report also shows clinical evidences of a representative case, and results achieved in 45 patients who were treated with Heberprot-P. This product becomes a valuable tool in expertise hands for treating patients suffering from that condition. The study was aimed to evaluate the efficacy and safety of the intralesional administration of Heberprot-P in DFUs. It was demonstrated that Heberprot-P improves the quality of life and decrease the amputation rates among these patients.

Keywords: Diabetic foot ulcer, amputation, Heberprot-P

Biotechnología Aplicada 2010;27:120-123

RESUMEN

Técnica no quirúrgica pero eficaz para el tratamiento del pie diabético. Una porción creciente de pacientes con úlceras del pie diabético (UPD) no responden favorablemente a los tratamientos habituales, lo que como resultado ocasiona la amputación parcial o total de una extremidad. Las UPD son un problema de salud que comprometen a diferentes especialidades médicas; en especial la Angiología y la Endocrinología. En el mercado no existen productos para el tratamiento de las úlceras grados 3 y 4, según la clasificación de Wagner, ni para úlceras extensas o con aspecto isquémico. Se efectuó un estudio observacional, descriptivo, longitudinal y prospectivo en 45 pacientes ingresados en el servicio de Angiología del hospital Julio Trigo López, con diagnóstico de UPD, desde enero a junio de 2010. Este reporte de casos aborda las evidencias clínicas de un caso y los resultados relevantes en 45 pacientes tratados con Heberprot-P, como una herramienta más en manos expertas para el tratamiento de los pacientes con esta enfermedad. El objetivo es evaluar la eficacia y seguridad de la administración intralesional del Heberprot-P, en las UPD. Se concluyó que el Heberprot-P está contribuyendo a la mejoría de la calidad de vida y a disminuir las amputaciones en estos pacientes.

Palabras clave: Úlcera del pie diabético, amputación, Heberprot-P

Introduction

According to estimates of the World Health Organization (WHO), there are currently 177 millions of patients suffering diabetes mellitus (DM), 90% of them type 2, and 370 millions of people have been predicted for the year 2030 having this disease with a tremendous impact for health systems [1, 2].

The prevalence of DM was 33.3 x 1000 inhabitants in the year 2006 in Cuba [3]. In Spain, there were estimated that 10 to 15% of people carry this illness [4], with 7.5% prevalence among the general population in the European Union. It was reported that approximately 17.7 millions of people have been diagnosed with DM in the United States of America, and there are 31.7 and 17.8 millions suffering this disease in India and China, respectively [5].

The diabetic foot is among the most feared complications of DM. This is a complex condition, defined by the Spanish Society of Angiology as "a clinical ul-

ceration of etiopathogenic neuropathic origin which is induced by sustained hyperglycemia together with the incidence of predisposing (neuropathy, arthropathy), triggering (external or internal trauma caused by bone deformities) and aggravating arteriopathy and infection) factors, all of them ending in a wound or ulcer in the diabetic foot (DFU)" [6].

DFU is a frequent complication among diabetic patients, with an approximate annual incidence of 2% in the world, and a prevalence of 2 to 10% for a given region [7]. It has been estimated that 15% of DM patients develop at least one ulcer during their life, the most affected ones been 45 to 65 years old [8] and 10 to 30% of them requiring an amputation [9]. This last is also favored by infection, been reported approximately 60% of all the amputations as due to infected wounds [10]. This also influences in the mortality among DM patients, since 50 to 60% of patients

1. Wild S, Rogli G, Green A, Sicree R, King H. Global prevalence of diabetes: estimates for the year 2000 and projections for 2030. *Diabetes Care* 2004; 27(5):1047-53.

2. Venny C, González B, Lanfranchi G, Hervy MP. Impact du diabète chez les sujets en charge et traitement de l'hyperglycémie. *Soins Geret* 2009; 76(1):18-21.

3. Anuario estadístico de Salud 2006. Ministerio de Salud Pública, Cuba.

4. Goday A. Epidemiología de la diabetes y sus complicaciones no coronarias. *Rev Esp Cardiol* 2002;55:657-70.

5. Delgado E. Epidemiología del pie diabético. *ReES* 2007;7(2):55-8.

receiving a lower limb amputation dye within the next five years [11]. Lower limb arteriopathy at the onset of DM is described in 8 to 10% among diagnosed patients, progressively increasing to 15% after 10 years and reaching up to 50% following 20 years of DM evolution [12].

Therefore, the economical impact of DM for a given country will depend on the prevalence of the disease and the incidence of its chronic complications. More than one million of amputations will be caused by this condition, unless a medicine able to heal the huge and complex DM ulcers will be available [13]. In this context, the Center for Genetic Engineering and Biotechnology (CIGB) of Havana, Cuba, has developed a medication based on the human recombinant Epidermal Growth factor (hrEGF), denominated Heberprot-P [14], which has been extensively applied in Cuba and Venezuela. In this work, we show the results obtained with the technique used for the application of this product for treating DFUs. The aim is to report the efficacy and safety of the intralesional delivery of Heberprot-P in DFU, based on the location of the treated wounds, their type and the procedure used, correlated with the attained therapeutic response, and its impact on reducing the risk for amputation.

Materials and methods

An observational, descriptive, longitudinal and prospective study was carried out to evaluate the therapeutic response of DFU patients who were treated with Heberprot-P. The study was conducted at the angiology service of the General Teaching Hospital Julio Trigo, located in the Arroyo Naranjo municipality in Havana, Cuba, from January until June, 2010.

Treatment was applied to 45 patients diagnosed as having a complicated DFU, who were previously indicated for complete amputation of the affected limb, and already receiving the sanitary-dietetic medical treatment indicated for these conditions (metabolic control with multiple doses of insulin, antibiotic therapy, and minor surgical procedures, depending on the location, type and extension of the wound). They were initially admitted at the service, and administered by intra and perilesional routes with Heberprot-P (25 and 75 µg), daily or in alternate days, depending on their clinical improvement. The patients were randomly distributed among groups. A patient was selected as case study to show graphic evidences of his evolution (Figure).

Heberprot-P is a lyophilized, sterile product, free of preservative and designed for intra and perilesional delivery. It contains hrEGF as active principle, and presented in 25 and 75 µg vials.

Once dissolved in injection water, it was infiltrated by using the adequate thin needle, starting at the deepest areas towards the periphery of the lesion, distributing it in small doses. The proper antiseptic measures were taken into consideration to avoid the spread of any infection.

Heberprot-P was administered according to the evolution of the wound and the time, both required for each patient to achieve full granulation, the reduction of the wound area, and the presence or absence of any criteria indicative of the need to apply an invasive procedure. All the patients received doses of fast and intermediate insulin, also been indicated for the

common complementary analyses as established for this condition (complete blood cell count, hematocrit, eritrosedimentation, electrocardiogram, foot X rays, culture and antibiogram as required, glycosylated hemoglobin, and Doppler analysis). The wounds were also photographed at the beginning and the end of treatment, with the prior consent of the patient.

The reported adverse events were treated according as established for their intensity and severity (Table 1).

Personal details of the selected patient

Patient ELF, a white male, 43 years old, with pathological records of type 2 DM for 15 years that was controlled with a single dose of 25 units of slow insulin every morning. He is moderately obese, with a body mass index of 35 kg/m², arterial hypertension, and bronchial asthma grade 3 which is controlled by salbutamol treatment.

Description of the case

The patient arrived to the angiology service of the Julio Trigo López hospital in Havana City, on February 9th, 2010. He referred of receiving a puncture through the shoe on its right foot a few days ago, and his Family Doctor indicated treatment with one vial of fast-slow penicillin administered intramuscularly every 12 h, and dipyrone for fever and pain. He was asleep for two days because of pain at the injured foot, also having numbness on the other foot mainly at noon.

The following parameters were determined at physical examination:

General parameters: Body temperature of 39.5 °C

Right lower limb: A puncture orifice was detected at the head of the first metatarsal, with an inflammatory cavity filled with pus, releasing a purulent secretion through the orifice. Edema was present, extending to the middle third of the leg, with localized heat, and pain at palpation and when moving the foot. The peripheral arterial pulses (femoral, popliteal, posterior tibial and pedal) were detected in both legs.

Neurology: Decreased superficial sensitivity

Urgent complementary diagnostic tests:

Glycemia: 17.5 mmol/L

Hemoglobin: 111 g/L

Leukograma:

Leukocytes: 13.7 x 10⁹/L

Complete blood cell count: P 0.86; L 0.10; M 0.04

Radiology: X rays of the forefoot, back of the foot and lateral of the right foot. No signs of gas in the soft areas were detected, neither osteomyelitis nor osteolysis.

Electrocardiogram: Normal

Diagnosis

Diabetes mellitus, complicated

Neuroinfectious diabetic foot (abscessed), grade 3 according to Wagner's classification

Table 1. Adverse events

Adverse event	Intensity	Proposed therapeutic action
Shivering and chills	Mild to Moderate	Difenhydramine (20 mg) i.m.
Tiritona y escalofríos	Mild to Moderate Severe	Hydrocortisone (1 g) i.v. + parenteral hydration
Other less frequent	-	According to the symptoms

6. Marinello J, Blanes JI, Escudero JR, Ibáñez V, Rodríguez J. Consenso sobre pie diabético. *Angiología* 1997;49(5):193-230.

7. Frykberg RG, Zgonis T, Armstrong DG, Driver VR, Giurini JM, Kravitz SR, et al. Diabetic foot disorders: A clinical practice guideline (2006 revision). *J of Foot & Ankle Surg* 2006;39 Suppl 5:S1-S66.

8. Reiber GE. The epidemiology of diabetic foot problems. *Diabet Med* 1996;13 Suppl 1:6-11.

9. Lipsky BA. Medical treatment of diabetic foot infections. *Clin Infect Dis* 2004;39 Suppl 2:S104-14.

10. Dinh TL, Veves A. A review of the mechanisms implicated in the pathogenesis of the diabetic foot. *Int J Low Extrem Wounds* 2005;4(3):154-9.

11. Simmons Z, Feldman EL. Update on diabetic neuropathy. *Curr Opin Neurol* 2002;15(5):595-603.

12. Marinell J., Carreño P, Estadella B. Capítulo VI. Procedimientos diagnósticos en el pie diabético. En: *Tratamiento de Pie Diabético*, Ed. Jarpyo, Barcelona 2002; p. 71-83.

13. Valdés S, Rojo-Martínez G, Soringuer F. Evolución de la prevalencia de la diabetes tipo 2 en población adulta española. *Med Clin (Barc)* 2007;129:352-5.

14. Heberprot-P - Atención integral al paciente con pie diabético + Heberprot-P (sitio web). Disponible en: <http://heberprot-p.cigb.edu.cu/> (Consultado: 30 de agosto de 2010).

General procedure, suited to the individual characteristics of treated patients

1. Admission at the Angiology service
2. Emergency complementary diagnostic tests
3. Emergency surgery: Patient placed in supine position, being administered with local anesthesia at the supramalleolar level on the affected foot. Foot nerves were blocked with lidocaine qs., and the foot and leg were disinfected with iodated alcohol or thymerosal. An incision was applied to the abscess at the level of the head of the first metatarsal, pus was drained and the sloughed tissue was debrided with Meserbaum scissors to almost the periosteum, trying not to expose the joint capsule. The sloughed flexor tendon of the first toe was resected. The phlyctena was removed from the top of the foot, exposing an area and the tendinous fibers of the extensor of the first toe without ulcer. The rest of the foot was preserved, showing abundant bleeding. The residual wound was cleaned with iodine solution, further subjected to hemostasis, treated with 10% povidone iodine, and subsequently occluded with cotton dressing and finally covered with a bend dressing.
4. Metabolic control: The patient must be always insulinized. Dosage can be distributed in four doses of either fast or intermediate insulin, according to the combined schedule of fast (20% at breakfast, 30% before lunch, 30% before dinner) or intermediate (20% at 10:00 pm) insulin, respectively.
5. The total dose of insulin administered to the patient should be taken as reference for following treatment once tested by Benedict's after breakfast, lunch and dinner and at 10:00 pm, for a proper metabolic control and to adjust treatment attending to the patient's needs for insulin.
6. Wide spectrum antibiotics should be indicated empirically or following the antibiotic policy of the Service; generally starting with a first generation cephalosporin together with metronidazole i.v. in cycles of ten days, and being adjusted based on patient evolution or culture and antibiogram results.
7. Adjustment of the usual treatment indicated for other background pre-existing diseases of the patient.
8. Complementary tests essential to define other associated complications.
9. Heberprot-P treatment must be started as soon as possible once controlling the infection, administering it intra and perilesionally.
10. The first toe was amputated in a second surgical procedure, because of being compromised by ischemia and with sepsis extending throughout the length of the flexor tendon of the foot, and Heberprot-P continued to be administered.

Results and discussion

The main results of the last phase of the first six months of 2010 are shown in table 2, and graphic evidences of a clinical case (Figure).

Treatment

Heberprot-P (75 µg) started to be applied on the third day, once observing scarce serohematic secretion and after resecting the sloughed tissues with scissors and forceps on the daily cure at the Angiology Service. The

Table 2. Main results of the applied Heberprot-P treatment in diabetic foot ulcer patients, during the first six months of 2010, at the angiology service of the General Teaching Hospital Julio Trigo, Havana, Cuba

Parameters	Dosis 25 µg	Dosis 75 µg	Total
Number of patients	22	23	45
Abandoned	-	2	2
Adherence to treatment	22	21	43
Complete granulation in			
2-4 weeks	13	11	24
4-6 weeks	6	8	14
6-8 weeks	3	2	5
Complete granulation in			
2-4 weeks	12	7	19
4-6 weeks	8	10	18
6-8 weeks	2	4	6
Adverse events	35	47	82
A1c glycosylated hemoglobin (%)			
6 ≤ A1c < 8	8	4	12
8 ≤ A1c < 10	9	11	20
10 ≤ A1c < 12	3	3	6
12 ≤ A1c ≤ 14	2	3	5

product was administered first at the deepest wound areas and further in the periphery, prior disinfection with sodium chloride. The remaining sloughed tissues were resected on each cure, the patient showing a progressive clinical improvement under an adequate metabolic control. The patient was discharged after 15 days of treatment and followed up at the outpatient service three times a week for administering Heberprot-P.

In the last week, he showed granulation in more than 70% of the wound, with epithelialization and cicatrization areas, and small areas almost completely cicatrized. He also have a fine metabolic control and good hemodynamic stability. Twenty four doses of Heberprot-P were administered.

The evolutionary, complementary tests were: 7.2 mmol/L glycemia, 125 g/L hemoglobin, weight loss of 8 kg in eight weeks.

It is considered as necessary to encourage those physicians who get into contact with diabetic patients to incorporate the knowledge on this new non-surgical technique of administering Heberprot-P for the treatment of diabetic foot ulcers. This is based on the fact that more patients will improve their quality of life with more specialists interested on extending the Heberprot-P treatment, because of reducing the amputation rates.

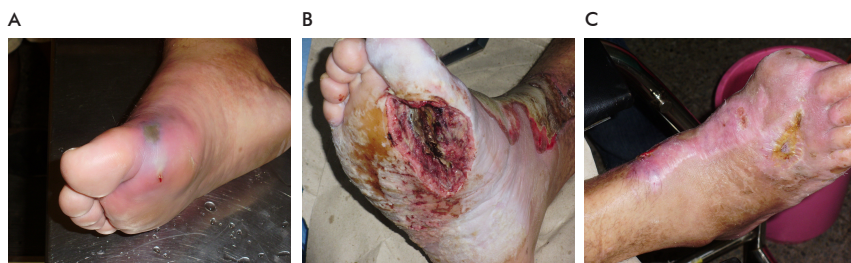


Figure. Evolution of patient ELF. A) Injury at the day of admission at the Angiology Service of the General Teaching Hospital Julio Trigo López, in Havana, Cuba (February 9th, 2010). It was generated by trauma at the level of the head of the first toe on the right foot. B) Start of treatment with Heberprot-P on February 12th, 2010. After several treatment sessions, sepsis extended to the middle third of the leg, showing signs of ischemia on the first toe which was amputated, and the sloughed tendinous fibers were resected. C) Cicatrization on April 16th 2010. Twenty four doses of Heberprot-P (75 µg) were

Conclusions

Heberprot-P induces the growth of useful and productive granulation tissue in a fast and consistent manner, even in ischemic wounds. The results obtained by our Angiology and Endocrinology team at the General Teaching Hospital Julio Trigo, in Havana, Cuba, demonstrated that more than 85% of the 45 patients

diagnosed with DFU and treated with Heberprot-P save their limbs from amputation, and the remaining patients at least decreased the extension of the initially indicated amputation. The case study patient returned to his normal working life, changing his lifestyle and dietary habits to more healthy ones with the joint assistance of our team and the appropriate supervision of the hospital's endocrinology service.

Received in August, 2010. Accepted for publication in September, 2010.